

ORAL SURGERY

ORAL MEDICINE

ORAL PATHOLOGY

ORAL AND MAXILLOFACIAL SURGERY*Editor: Larry J. Peterson*

Technique for stabilization of autogenous cancellous bone grafts in sinus lift procedures

David M. Momtaheni, DMD,^a Kenneth Schweitzer, DDS,^b and Frederick Muenchinger, DDS,^c New York and Bronx, N.Y. and Tampa, Fla.
COLUMBIA UNIVERSITY SCHOOL OF DENTAL AND ORAL SURGERY, ALBERT EINSTEIN COLLEGE OF MEDICINE, AND MONTEFIORE MEDICAL CENTER

Densely packed autogenous cancellous bone was stabilized in a sinus lift procedure with cortical cancellous struts. These struts were placed above the cancellous bone and rigidly fixed to the buttress and anterior sinus wall with titanium screws. This technique enables the clinician to maintain and stabilize bone graft materials in sinus lift procedures. (**ORAL SURG ORAL MED ORAL PATHOL** 1994;78:14-6)

One of the most challenging aspects of dental implant rehabilitation is the reconstruction of the atrophic maxilla. Atrophy confined to the alveolar region can be localized or generalized.

When atrophy is confined to the anterior region, the situation can be addressed by alveolar ridge augmentation and implant restoration. However, in the case of posterior maxillary atrophy, the condition is commonly complicated by maxillary sinus pneumatization. In selected cases, the most effective way to address the problem is maxillary antroplasty (sinus lift procedure). The procedure is well known^{1,2} but there are shortcomings in the described techniques with respect to the stabilization of the bone graft. This article describes a technique to immobilize the autologous bone graft within the sinus. Incision modifications for entering the maxillary sinus necessary for application of bone graft stabilization are also presented.

TECHNIQUE

An incision is placed superiorly and posteriorly in the maxillary mucobuccal fold creating two separate layers, mucosal-submucosal and muscular-periosteal.

^aAssistant Clinical Professor, Oral and Maxillofacial Surgery, Columbia University School of Dental and Oral Surgery, and Assistant Clinical Professor of Surgery, Albert Einstein College of Medicine.

^bProsthodontist, Assistant Attending, Montefiore Medical Center.

^cProsthodontist in private practice, in Tampa, Fla.

Copyright © 1994 by Mosby-Year Book, Inc.

0030-4220/94/\$3.00 + 0 7/12/55957

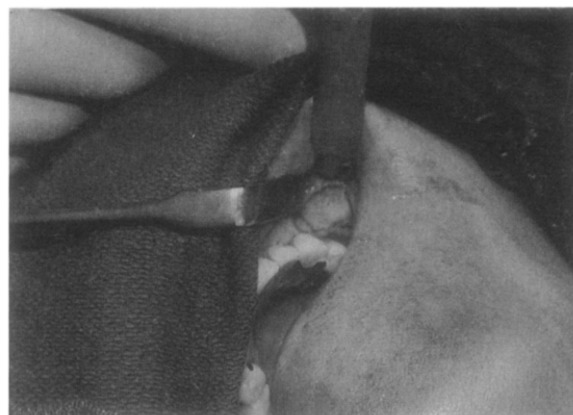


Fig. 1. Sinus entry at buttress area to provide solid foundation for fixation screw.

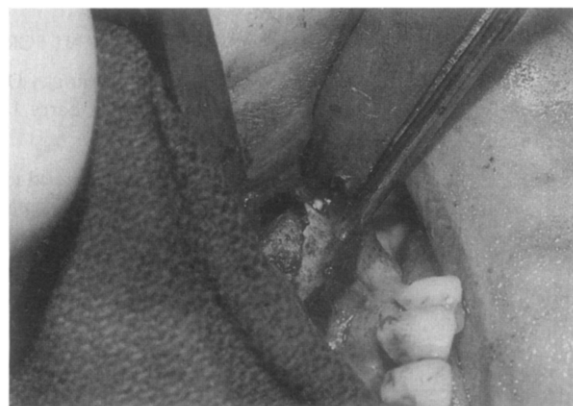

Fig. 2. Cancellous bone is rigidly stabilized with titanium screw.

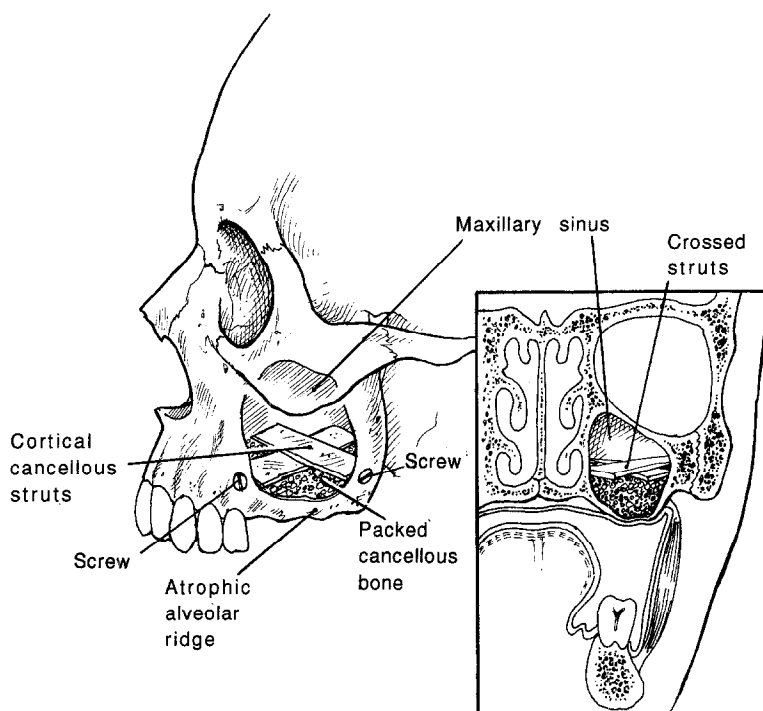


Fig. 3. Schematic view of corticocancellous struts held by titanium screws.

A 10×5 mm bony window is created posteriorly and superiorly with a bur. The bone in the window area and the associated schneiderian membrane are removed (Fig. 1).

Simultaneous bone harvest is performed from the anterior ilium. Using a reciprocating saw, a 3×5 cm corticocancellous block is removed from the medial table. An additional 20 cc of cancellous bone is harvested. The corticocancellous portion of the graft is split to create two 3×1 cm bone struts for graft stabilization. The cancellous bone is compressed in a syringe and packed into the floor of the sinus. The two corticocancellous struts are then placed in cross fashion superior to the cancellous bone. Two titanium screws are used to fix the cross struts to the buttress and anterior sinus wall (Figs. 2 and 3). Additional bone is then packed around the sinus entry window, and the wound is closed in two layers.

Implants are placed after a 4-month healing period with the use of conventional methods of implant insertion.

RESULTS

A total of five antroplastics have been performed with the use of this technique. Fifteen screw types titanium implants have been inserted into the grafted areas. Two implants were lost in two separate cases. These losses did not compromise the overall prosthetic rehabilitation.

DISCUSSION

In sinus lift procedures, the literature^{2, 8} suggests stabilization of bone graft material by using "a trap door" anterior sinus wall or by lifting the schneiderian membrane and packing the bone graft. Both techniques are impractical because the trap door is incapable of holding the corticocancellous graft material in the sinus. The sinus wall is too thin, too small, and, most of all, too unstable to provide support for the bone graft. Similarly, healthy schneiderian membrane is too thin and fragile to lift in an intact manner and therefore to provide roofing for the bone graft material. On the other hand, stabilizing the cancellous bone with corticocancellous struts will provide adequate support for the graft material. These struts can be easily placed by screw fixation or a combination of screw and titanium wire fixation.

CONCLUSION

On the basis of extensive literature³⁻⁶ support as well as our experience, stabilization of grafted bone material is an essential part of the technique of bone grafting. This crucial element has been inadequately addressed in the sinus lift procedure.^{7, 8} This technique will enable clinicians to provide bone stabilization during sinus bone graft augmentation procedures. Further study in the use of rigid fixation for maxillary antroplasty with bone graft augmentation is indicated.

REFERENCES

1. Block M, Widner S. Method for insuring parallelism of implants placed simultaneously with maxillary sinus bone grafts. *J Oral Maxillofac Surg* 1991;49:435-7.
2. Boyne PJ, James RA. Grafting of the maxillary sinus floor with autogenous marrow and bone. *J Oral Surg* 1980;38:613-6.
3. Breine U, Branemark PI. Reconstruction of alveolar jaw bone. *Scand J Plast Reconstr Surg* 1980;14:23.
4. Jensen J, Sindet-Pedersen S. Autogenous mandibular bone grafts and osseointegrated implants for reconstruction of the severely atrophic maxilla. *J Oral Maxillofac Surg* 1991;49:1277.
5. Jensen J, Krantz Simonson E, Sidet-Pedersen S. Reconstruction of the severely resorbed maxilla with bone grafting and osseointegrated implants: a preliminary report. *J Oral Maxillofac Surg* 1990;48:27-32.
6. Kahnberg K-E, Nystrom E, Bartholdsson L. Combined use of bone grafts and branemark fixtures in the treatment of severely resorbed maxillae. *Int J Oral Maxillofac Implants* 1989;4:297-304.
7. Keller EE, Van Roekel NB, Desjardins RP, et al. Prosthetic surgical reconstruction of the severely resorbed maxilla with iliac bone grafting and tissue-integrated prosthesis. *Int J Oral Maxillofac Implants* 1987;2:155-65.
8. Kent JN, Block MS. Simultaneous maxillary sinus floor bone grafting and placement of hydroxylapatite-coated implants. *J Oral Maxillofac Surg* 1989;47:238-42.
9. Lew D, Hinkle R, Unhold G. Reconstruction of the severely atrophic edentulous mandible by means of autogenous bone grafts and simultaneous placement of osseointegrated implants. *J Oral Maxillofac Surg* 1991;49:228-33.
10. Listrom RD, Symington JM. Osseointegrated dental implants in conjunction with bone grafts. *Int J Oral Maxillofac Surg* 1988;17:116-8.
11. Wood RM, Moore DL. Grafting of the maxillary sinus with intraorally harvested autogenous bone prior to implant placement. *Int J Oral Maxillofac Implants* 1988;3:209-14.

Reprint requests:

David M. Momtaheni, DMD
Rochefeller Center
630 Fifth Avenue, Suite 1868
New York, NY 10020