

A Partial Palatal Coverage Overdenture Retained by Zygomatic Implants

Daniel M. Schweitzer, DDS, FACP,¹ Mitchell J. Bloom, DMD,² & Gregorio O. Mancía, MDT³

¹Department of Prosthodontics, New York University College of Dentistry, New York, NY

²Department of Periodontology and Implant Dentistry, New York University College of Dentistry, New York, NY

³Private Practice, New York, NY

Keywords

Partial palatal coverage overdenture; zygomatic implants; atrophic maxilla; edentulism; cantilever prosthesis; risk factor.

Correspondence

Daniel Schweitzer, 133 E 58th St., New York, NY 10022. E-mail: dms560@nyu.edu

The authors deny any conflicts of interest.

Accepted February 20, 2015

doi: 10.1111/jopr.12312

Abstract

Prosthodontic rehabilitation of an atrophic edentulous maxilla can be challenging and is further complicated when multiple risk factors are present. Fixed prostheses require multiple implants for support/retention organized in biomechanically favorable positions in order to afford a good prognosis. Such suitable implant arrangements in an atrophic edentulous ridge can often be difficult to achieve. Removable prostheses require fewer implants for a favorable prognosis and can furthermore take advantage of the additional anatomical structures for support/retention. This clinical treatment will describe the fabrication of a partial palatal coverage overdenture retained by zygomatic implants.

Despite existing preventative public health strategies to prevent edentulism, it is a condition that will remain prevalent for the foreseeable future.^{1,2} The successful management of edentulism is critically important for the affected population with regards to oral and social function.¹ It has been established that the edentulous state is coupled with a continuous reduction in alveolar bone volume through time.²⁻⁴ As atrophy becomes more advanced, it can be more difficult to clinically create a satisfactory prosthodontic outcome.

Clinical situations with insufficient bone volume in the maxilla, due to pneumatized sinuses, bone resorption, or both, can necessitate extensive bone grafting, if even possible, for successful rehabilitation with conventional dental implants.⁵ The use of these augmentation techniques in such situations can involve multiple surgeries, increased morbidity, and extended definitive treatment time.⁶ An alternative to the use of conventional dental implants is the use of dental implants placed in more distant sites, such as the zygomata.

Dental implants can be used to support/retain both removable and fixed prostheses. The decision-making process during the diagnostic phase of treatment involves collecting and analyzing a wide range of information. Central to this is the number, size, and position of available implant(s) for a desired prosthesis. Moreover, in designing implant-supported/retained prostheses, favorable biomechanics involving the application of engineering concepts to restore function of the stomatognathic system can play a critical role in the prognosis of treatment.^{7,8} In splinted, cross-arch prostheses, the geometric configuration

of available implants relative to anterior-posterior spread becomes paramount when considering the use of cantilevered prostheses.⁹ The application of cantilevers can potentially increase the risk of hazardous torque and bending moments on a prosthesis, negatively affecting prognosis.⁹⁻¹¹ Zygomatic implants are placed at a 30° to 65° angle relative to occlusal force impact, are up to 50+ mm in length, and embedded only approximately 10 mm to 15 mm into the zygomatic bone. Additionally, because they often engage only limited amounts of crestal bone, which offers little to no support, zygomatic implants can present a considerable cantilever, which should be properly accounted for during treatment planning to minimize these potentially damaging forces.¹²⁻¹⁴

The standard recommended protocol for zygomatic implant-supported/retained prostheses includes cross-arch stabilization to minimize mechanical stress on the implants.^{5,13} Zygomatic implants usually offer prosthetic platforms in the maxillary premolar/canine areas. Hence, when one contemplates zygomatic implant-supported fixed prostheses, anterior support, preferably near the midline for the best geometrical triangulation relative to the occlusal plane via use of a conventional endosseous implant(s), is often used to minimize the potential deleterious effects of the zygomatic implants' cantilever.^{6,14} If a zygomatic implant clinical scenario presents with the impossibility of one or more anterior implants, the use of removable prostheses can allow the clinician to use the existing soft tissue to additionally support the prosthetic system. In the presence of a robust residual ridge with implants employed to provide retention,

the palatal area may be less important as a load-bearing area for removable prostheses. In such situations, the lateral palatal walls can effectively counteract oblique functional forces limiting stress on retaining abutments.¹⁵ It has also been reported that partial palatal coverage prostheses are often preferred by patients, allowing more space for the tongue and exposure of palatal tissue, enhancing food taste and texture appreciation.¹⁶

This clinical report describes treatment by use of a partial palatal coverage overdenture, retained by four zygomatic implants. It is specifically designed to allow occlusal force to be transmitted to the existing supportive maxillary soft tissue and to the zygomatic implants solely between the two right and left implant pairs, not on the anterior extension of the stabilizing bar, eliminating the bar as a source of cantilever extension. This design can serve to minimize problematic occlusal force conduction to the zygomatic implants.

Clinical report

A 69-year-old Caucasian woman presented with the chief complaint of "I have loose upper implants supporting my removable bridge." Her medical history included breast cancer in 1995, which was treated with a mastectomy and chemotherapy with no recurrence to date. Alendronate (Fosamax[®], dosage unknown) had been prescribed for osteoporosis diagnosed in 2003 and was maintained until approximately 2009. With this regimen she experienced no overt side effects, but did have concerns regarding possible risks given media attention. As a result of these concerns, the patient discontinued taking Alendronate and replaced it with a regimen of calcium supplements, which she was advised to discontinue following a myocardial infarction in 2012. Subsequent to this cardiovascular event, the patient has been maintained on a regimen of Carvedilol (3.125 mg twice daily), Simvastatin (40 mg daily), and aspirin therapy (81 mg daily). Consultation with her physician recommended no limitations to treatment and that her cardiac status was stable, and her progress quite favorable.

Her dental history included regular prophylactic visits twice a year, and she exhibited favorable oral hygiene. Clinical examination showed five endosseous root-form dental implants present in the maxilla occupying the former sites of teeth #2, #4, #6, #11, and #13 retaining a partial palatal coverage overdenture. The existing implants were not splinted and used Locator[®] attachments (Zest Anchors, Escondido, CA) as their retentive mechanism. All of the maxillary implants showed evidence of peri-implantitis as they exhibited bleeding upon gentle probing, clinical signs of overt inflammation, and severe, radiographically evident bone loss consistent with deep clinical peri-implant probing depths. The soft tissue on the crest of the edentulous maxillary ridge areas was thickened and mobile relative to the underlying bone. The implant in the #6 position exhibited mobility and had lost osseointegration. Teeth #17 and #22–27 were present in the mandibular arch along with endosseous root-form dental implants in former tooth sites #21, #28, and #30. All existing mandibular implants appeared to be in a healthy and maintainable state, and they, along with tooth #17, supported a removable partial denture. Radiographic exam revealed no evidence of pathology save the aforementioned. The patient reported that all present implants were placed

approximately 6 years previously. The edentulous Prosthodontic Diagnostic Index classification for the maxilla was IV. The implant in the #6 position was removed without compromise to the function or comfort of the existing prosthesis. The patient chose not to replace the lost implant. Despite efforts to maintain the remaining implants, in subsequent periodic dental visits the dental implant in former tooth site #2 failed approximately 10 months later, followed by failure of the implant in former tooth site #4 at 11 months; both exhibited mobility and were removed.

The removal of these implants resulted in compromised retention of the existing prosthesis. The remaining osseointegrated implants (#11 and #13) continued to demonstrate ongoing inflammation with severe bone loss and were considered unsuitable for supporting a prosthesis due to poor prognosis. After full evaluation and diagnosis, treatment options were presented to the patient including conventional complete denture therapy. Use of traditional root-form endosseous dental implants to support/retain a prosthesis offered a guarded prognosis because of the patient's dental history of multiple implant failures in conjunction with a medical history that included the use of oral bisphosphonate therapy. An alternative dental implant option using zygomatic implants was considered, and would negate the need for bone grafting. The patient was advised that the effect of oral bisphosphonate therapy on zygomatic implants is currently unknown. The patient elected the treatment plan that included the placement of zygomatic implants to retain a partial palatal coverage overdenture.

A board-certified oral and maxillofacial surgeon initiated rehabilitation with the removal of the remaining endosseous implants and placement of prosthetically driven zygomatic implants in former tooth sites #4 (45 mm), #5 (52.5 mm), 11 (52.5 mm), and 13 (50 mm) (respectively: #34737, #34740, #34740, #34739, Nobel Biocare, Zurich, Switzerland), via the sinus slot, two-stage placement technique. The existing implant-supported partial palatal coverage overdenture was converted immediately into a conventional provisional complete denture with intaglio surface relief over the surgical sites. The zygomatic implants were left submerged to heal for approximately 6 months, upon which stage 2 uncovering surgery was performed and osseointegration clinically verified for all four implants. To provide immediate cross-arch stabilization of the exposed zygomatic implants, the existing provisional removable complete denture was converted into a screw-retained fixed prosthesis the day of stage 2 surgery. Subsequent to a period of healing after the stage 2 surgery, full-arch alveoplasty of the maxilla was performed by a board-certified periodontist to remove the irregularly contoured and thickened mobile soft tissue and provide a firm, stable base to assist in supporting the definitive removable prosthesis. Some of the excised tissue obtained during the alveoplasty was dense keratinized tissue; this tissue was trimmed and used to enhance the zone of attached keratinized peri-implant tissue as a subepithelial connective tissue graft. After proper healing time for the alveoplasty, allowing for sufficient ridge morphologic maturity, fabrication of the definitive prosthesis began.

A preliminary impression was made of the maxillary arch with irreversible hydrocolloid (Jeltrate; Dentsply Caulk, Milford, DE) in a stock aluminum tray. The preliminary cast was poured of this impression (Buff Stone; Whip Mix, Louisville, KY), and a custom impression tray was fabricated,

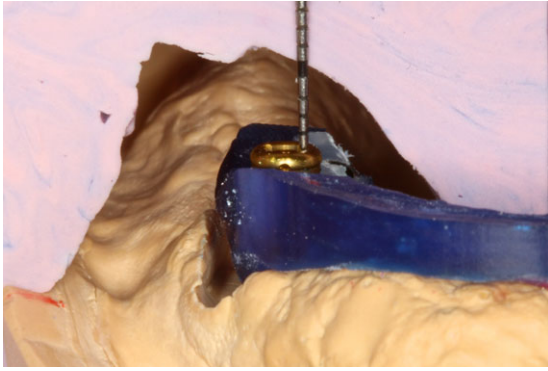


Figure 1 Silicone index being used to evaluate space available for prosthetic material.

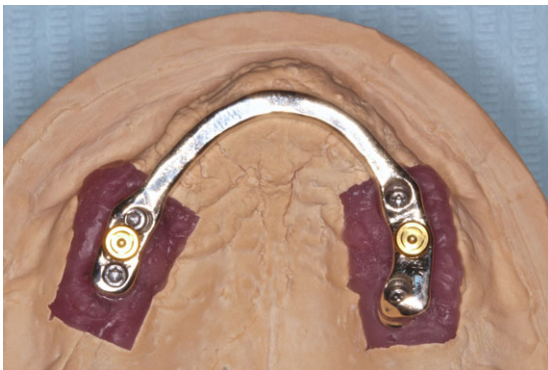


Figure 2 Occlusal view of cast stabilizing bar with Locator® attachments tapped.

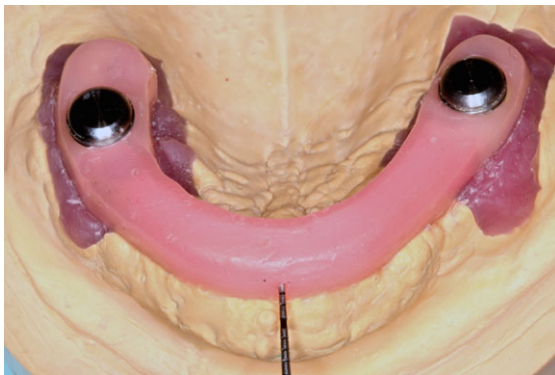


Figure 3 Cast stabilizing bar with 1 mm relief provided by baseplate wax.

with raised windows (to allow sufficient impression material bulk to stabilize the implant impression copings) for impressing the zygomatic implants, using a light-polymerized urethane dimethacrylate acrylic (UDMA) (Megatray; Select Dental, Farmingdale, NY). The maxillary tray was border molded with a thermoplastic modeling compound (Impression Compound; Kerr, Orange, CA). The implant impression tray raised windows were heat sealed with baseplate wax (Corning Rubber; Ronkonkoma, NY). Open-tray, fixture-level implant impression

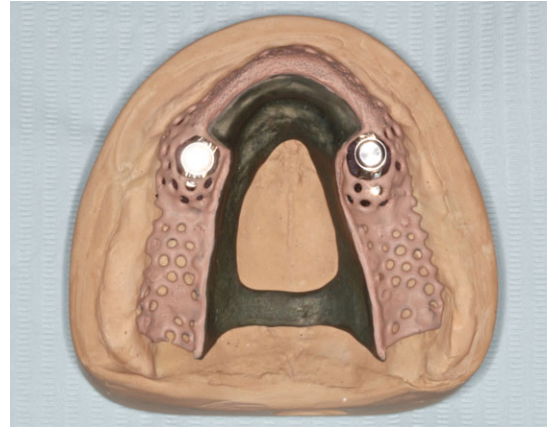


Figure 4 Occlusal view of cast and opaquest framework for removable prosthesis.

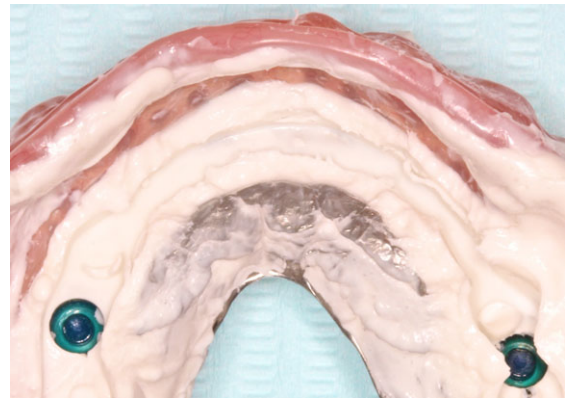

Figure 5 Occlusal view of intaglio surface of anterior portion of removable prosthesis after maximum incisal occlusal force application. Note no areas of show through throughout the bar channel, although pressure areas are demonstrated on the crestal/buccal aspect of the residual ridge and anterior palate, providing soft-tissue support under occlusal load.

copings (#29072; Nobel Biocare) were placed on all four zygomatic implants. A final impression was made with a polyether impression material (Permadyne; 3M ESPE, St. Paul, MN). Laboratory analogs were connected to all four implant impression copings, and the impression was poured using type IV dental stone (Ultirock; Whip Mix) to create the final master cast.

A pink baseplate wax (Corning Rubber; Dow Corning, Midland, MI) occlusal rim on a light-polymerized UDMA record base (Triad; Dentsply Caulk) was made on the final master cast. The occlusal rim was tried and adjusted in the patient's mouth, and a facebow transfer and centric relation record were made. The final master cast was then mounted on a semi-adjustable articulator (1620 AR; Panadent, Colton, CA) against the mandibular cast. Following tooth shade and mold selection (BlueLine; Ivoclar Vivadent, Amherst, NY), a preliminary trial denture with a lingualized artificial tooth arrangement in bilateral balance was created. The maxillary preliminary trial denture was tried in the patient's mouth and adjusted for esthetics, phonetics, and function. The final master cast was indexed on its border with three notches created by a

rotary fissure instrument, and a silicone index (Lab Putty Base; Coltene/Whaledent, Cuyahoga Falls, OH) was prepared of the trial denture on the final master cast.

Subsequently, the silicone index was sectioned three times in the areas of the midline and between the two left and two right implants. A resin pattern (Pi-Ku-Plast HP; Bredent, Senden, Germany) for a rigid cross-arch stabilization bar for the zygomatic implants was created. The dimension of the stabilizing bar was approximately 3 mm bucco-palatally by 2.5 mm incisocervically, with 0.5 mm to 1 mm of soft tissue separation. The attachment system (Locator[®]) was selected for its low vertical profile and effective retentive force. The Locator[®] attachment matrix was tapped on a milling machine (APF 300; Ivoclar-Amann, Koblach, Austria) to enable servicing of the attachment in the future. Two attachments were tapped, one between each pair of zygomatic implant connections. The threaded portion of the attachment is 2 mm horizontally and 2.03 mm vertically. With these dimensions the zygomatic implants needed to be at least 4 mm apart to ensure a 1 mm thick circumferential wall around the Locator[®] attachment for support.

The sectioned silicone indices were then seated on the final master cast for measurements of available prosthetic space from the attachment level (Fig 1). It is recommended that approximately 2 mm of acrylic surround the matrix component of the Locator[®] attachment. Additionally, a minimum of 2 mm of artificial tooth thickness is recommended for a good long-term prognosis. Measurements were also made at the midline to ensure proper prosthetic space surrounding the stabilizing bar. The stabilizing bar was designed to only brace the implants and not contact the denture, thus avoiding extension of the already existing cantilever created by the zygomatic implants. To accomplish this, 2.5 mm of prosthetic space was desired above the bar. This included approximately 1 mm of relief to allow for passive occlusal load compression and 1.5 mm thickness of major connector of the partial palatal coverage overdenture. Upon satisfaction of the prosthetic dimensional requirements, the stabilizing bar was cast and finished in type IV gold alloy (J3; Jensen, North Haven, CT), and the matrix Locator[®] attachments were tapped into place (Fig 2).

The fit of the stabilizing bar was verified intraorally via the one-screw test. The stabilizing bar was then placed back on the final master cast, and pink baseplate wax (Corning Rubber) was used to create approximately 1 mm circumferential relief around the bar, save the connected Locator[®] attachment complexes (Fig 3). This relief would create a channel within the intaglio surface of the prosthesis designed to avoid contact with the stabilizing bar. Additional relief of 0.5 mm was created with green wax (#40194 Stippled Casting Wax, Bego, Bremen, Germany) for areas involving meshwork for the prosthesis to ensure proper engagement of and support for the denture acrylic. No additional relief was used for areas involving the major connector. A silicone impression (Z-Dupe; Henry Schein, Melville, NY) was made of the relieved final master cast, and a refractory cast was poured (Wirovest; Bego).

The overdenture framework design was then verified at the wax-up stage (#40194 Stippled Casting Wax; Bego; #6883009 Circular Retaining Wax; Renfert, Hilzingen, Germany; #1015203LL Wire Wax Round Blue 18GA; Zahn Dental, Melville, NY) on the refractory cast. The main design features

included the following: (1) A palatal strap major connector; (2) Meshwork over accessible areas of the residual alveolar ridge (the distal extensions and buccal aspect of the anterior ridge not obstructed by the stabilizing bar). This allows the primary stress-bearing areas to be relined in the future to counteract ridge atrophy; (3) A relieved area (~1 mm) to eliminate overdenture framework/stabilizing bar contact; (4) Retention beads for acrylic adherence incorporated onto the framework where meshwork/acrylic interface would possibly prove bulky. The resulting design provided for the Locator[®] attachments as the only connection between the zygomatic implants and the prosthesis.

The framework was cast in a cobalt-chrome alloy (#50065 Wironium; Bego) with an induction casting machine (Nautilus CC Plus; Bego) and opaqued (IPS d.SIGN Gingiva Opaquer; Ivoclar Vivadent) (Fig 4). The matrix Locator[®] attachments were incorporated into the laboratory-fitted framework on the final master cast with autopolymerizing acrylic resin (Pro Tech Plus; Boynton Beach, FL). The framework's clinical fit was verified intraorally with visual inspection and a silicone disclosing agent (Fit Checker; GC, Tokyo, Japan). Following this, an artificial tooth rearrangement in bilaterally balanced lingualized occlusion was fabricated in baseplate wax with the aid of the sectioned silicone indices. The final maxillary trial denture and stabilizing bar were tried in the patient's mouth and adjusted for esthetics, phonetics, and function. Upon establishment of a satisfactory artificial tooth arrangement, the denture was heat-cure injection processed (SR Ivocap; Ivoclar Vivadent) with heat-polymerized methyl methacrylate resin (SR Ivocap High Impact; Ivoclar Vivadent). The cured denture was remounted on the articulator and corrected for processing errors. The denture was equilibrated to achieve bilaterally balanced lingualized occlusion. Blue 1.5 lb Locator[®] nylon inserts were used to retain the denture. The bilateral balanced occlusal scheme was verified intraorally. Pressure Indicating Paste (Mizzy, Myerstown, PA) was used to adjust for soft tissue pressure areas. Subsequently, a silicone disclosing agent (Fit Checker) was used in conjunction with full incisal masticatory force to ensure the denture did not touch the stabilizing bar in function; two adjustments were performed with a rotary fissure instrument on the intaglio surface of the removable framework near to midline where the occlusal surface of the stabilizing bar made contact. The final silicone disclosing agent evaluation demonstrated no contact between the stabilizing bar and the prosthesis with incisal occlusal force application (Fig 5). The stabilizing bar was torqued intraorally to 32 Ncm, and the denture was then placed in the patient's mouth on a trial basis (Figs 6, 7). Homecare and oral hygiene instructions were given to the patient. The patient returned for follow-up 1 week later, and she reported being satisfied with the prosthesis. She was placed on periodic recall.

Discussion

The selection criteria driving the decision to use a removable prosthesis to restore the maxillary dentition in this treatment were numerous. Chief among them were a need for lip support and the evaluation of optimal tooth position relative to the residual ridges and implant position. These suggested a contraindication to a fixed prosthesis because of the need for a

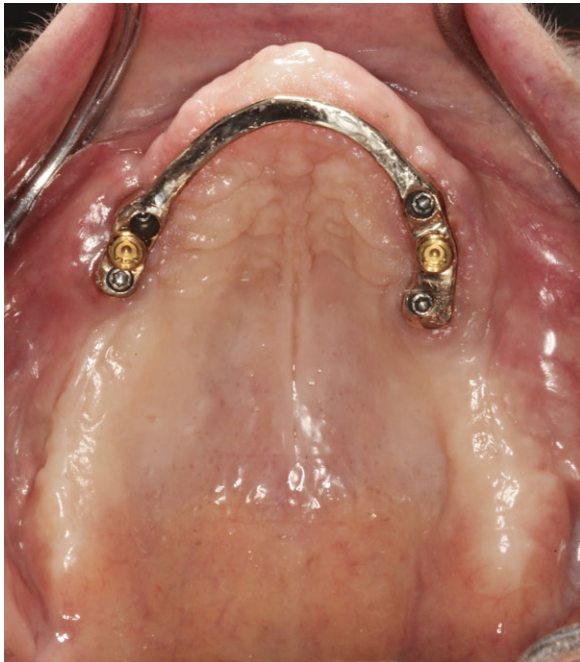


Figure 6 Occlusal view of inserted zygomatic implant stabilizing bar.

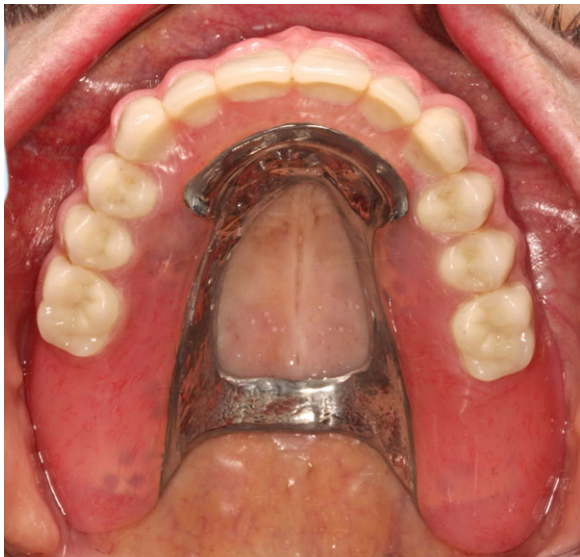

Figure 7 Occlusal view of inserted definitive prosthesis.

ridge-lap design offering poor access to proper hygiene and the creation of a biomechanically unfavorable intraoral cantilever extension, respectively. The concern for proper oral hygiene was clearly evidenced during the provisionalization phase, in which the patient's modified denture was used as a fixed prosthesis. She exhibited inability to preform even marginally acceptable plaque control. An additional aforementioned factor was the ability with a removable prosthesis to take advantage of all supportive elements in the maxillary jaw (implants, residual ridges, and musculature) to counter the potentially damaging forces of occlusion and function.

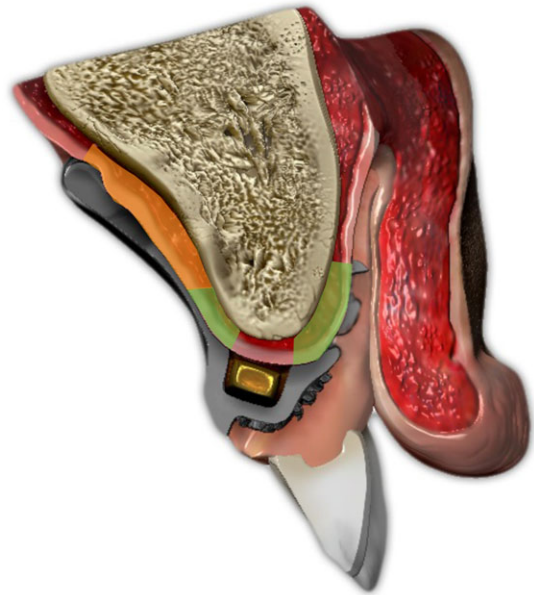


Figure 8 Cross-sectional diagram of the prosthesis through tooth #7 demonstrating available soft tissue support. The highlighted green areas indicate the primary stress-bearing area of the residual alveolar crest. Note, the crestal area relieved circumferentially around the stabilizing bar offers no support. The highlighted orange area indicates the secondary stress-bearing area of the anterior palate. Upon compression under occlusal load, these stress-bearing areas prevent the prostheses from contacting the relieved stabilizing bar, preventing cantilever extension of the prosthodontic system.

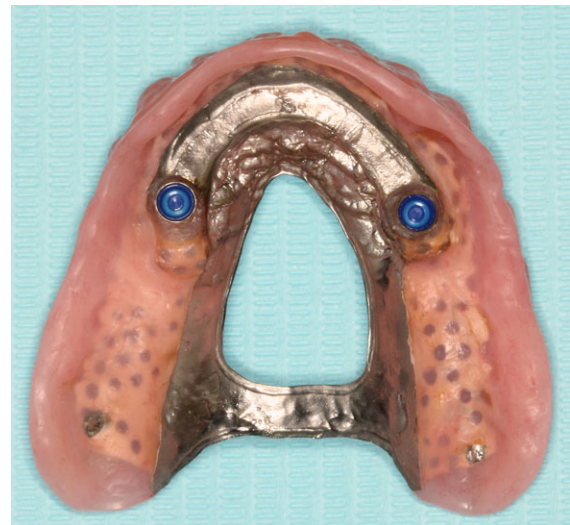

Figure 9 Intaglio view of removable prosthesis that illustrates the channel design that avoids contact with the stabilizing bar, save the Locator attachments on which it pivots, in masticatory function.

The rationale for cross-arch stabilization of zygomatic implants emerges from the fact that their only significant stabilization may come solely from the zygomata themselves, not the residual maxilla.^{5,13} The contribution of any stabilizing zygomatic implant osseointegration associated with the residual

ridge is unknown.¹⁴ This potentially creates a cantilever from supporting zygomata to the prosthetic platform inherent with this type of treatment and cannot be modified by change in prosthesis design. Rigidly splinting the four zygomatic implants used in this treatment makes them physically stronger as a braced group. This configuration can dissipate potentially injurious occlusal forces over more bone/implant surface area, as opposed to each implant individually confronting these forces.

A primary impetus for the described design of the removable prosthesis was to minimize the amount of potentially damaging force generated by this considerable cantilever intrinsic to zygomatic implant supported/retained dental prostheses. A fixed restoration in this treatment would have extended the zygomatic implant cantilever approximately 17 mm anteriorly. This length was calculated by identifying an axis through the two most anterior implants, and then measuring a nearly perpendicular line from the this axis to the embrasure between the central incisors of the prosthesis. The magnitude of the generated force is directly related to the length of the cantilever, and can often create compressive and/or tensile loads on the implants greater than twice the initial occlusal force application.⁷ Therefore, the desire was to not voluntarily extend the cantilever with the inserted prosthesis. The deleterious force generation can stress and fatigue the supportive implant system, and, as previously mentioned, potentially lead to biomechanical breakdown. Moreover, there are essentially two cantilever systems to consider: (1) the cantilever from the most anterior incisal edges to prosthetic implant platforms; and (2) the cantilever from the most anterior incisal edges to the supportive zygomata. When debating either, the concept of limiting bending moments and biomechanical strains on the involved prosthetic system will always ring true.^{8,9,12} The presented design directs occlusal force to the zygomatic implants solely between the two right and left implant pairs, not on the anterior extension of the stabilizing bar.

During masticatory function, the denture pivots on the Locator[®] attachment system while being supported by the maxillary primary and secondary edentulous stress-bearing areas (Fig 8). Because of this soft tissue support, the cantilever portion of the stabilizing bar is left untouched within the prosthesis intaglio surface channel (Fig 9). Hence, occlusal forces are directed more axially to the prosthetic platform of the zygomatic implants, using them more along the lines for which they were designed, and minimizing biomechanical stress impact.

The advantages of this described design relative to a fixed prosthodontic solution are numerous. In addition to minimizing the cantilever effect of the prosthesis, the use of a partial palatal coverage overdenture allows for potentially easier and more accurate/functional restoration of lost oral anatomy. The fabrication and maintenance cost is decreased, especially if less expensive alloys are used for the stabilizing bar, such as titanium or cobalt-chromium based alloys. The maintenance and repair of the prosthesis and supporting implants is greatly simplified. Lastly, hygienic procedures are enhanced by maximizing patient access to the implants, which can aid in minimizing the incidence of peri-implant disease.¹⁶ Disadvantages of the described design relative to a fixed prosthodontic solution include more potential maintenance considering the need for periodic intaglio acrylic surface relines/adjustments and replacement of worn Locator[®] components; increased residual

ridge pressure that may accelerate resorption; psychological/emotional hurdles regarding the acceptance of removable prostheses; possible development of combination syndrome if opposing a mandibular anterior natural dentition; and possible inflammatory reactions of denture-bearing mucosa.¹⁷

Ultimately, a fastidious clinician following established prosthodontic protocol is crucial for the viability of this treatment. Proper removable prosthesis extension through careful border molding is important for stability, retention, and support. Evaluation of the trial denture for satisfactory esthetics and phonetics and then relating this morphology to the stabilizing bar to ensure adequate prosthetic material dimension aids in maximizing treatment prognosis. The occlusal scheme, as developed in bilateral balance, distributes masticatory functional force to as much of the supporting structures as possible. This helps minimize soft tissue stress points and likely resultant bone resorption. Furthermore, a bilateral balanced occlusal scheme may diminish potential torque and bending moments applied to the zygomatic implants.¹⁸ It is well known that such forces induce possible bone loss around the supporting implants, screw loosening, and screw/implant/prosthesis fracture.^{7-11,18-20} Lastly, timely maintenance of the prosthetic system by the clinician is required.

Conclusion

Zygomatic implants offer a viable alternative treatment option for patients with atrophic edentulous maxillae. Because of the length and geometric configuration of the placement of these implants and the remoteness of the bony support offered by the zygomata, a biomechanically unfavorable cantilever is potentially created. During prosthesis fabrication, the clinician should consider using all available supporting structures in the oral cavity, including the edentulous ridges, if anterior endosseous implants are not available for use.

Acknowledgments

Thanks to Paul Zhivago, DDS, for creating the artwork for Figure 8 and Yoshi Chimura, RDT, for assistance with laboratory work.

References

1. Cooper LF: The current and future treatment of edentulism. *J Prosthodont* 2009;18:116-122
2. Felton DA: Edentulism and comorbid factors. *J Prosthodont* 2009;18:88-96
3. Atwood DA: Reduction of residual ridges: a major oral disease entity. *J Prosthet Dent* 1971;26:266-279
4. Tallgren A: The continuous reduction of the residual alveolar ridges in complete denture wearers: a mixed-longitudinal study covering 25 years. *J Prosthet Dent* 1972;27:120-132
5. Bedrossian E: Rehabilitation of the edentulous maxilla with the zygoma concept: a 7-year prospective study. *Int J Oral Maxillofac Implants* 2010;25:1213-1221
6. Candel-Marti E, Carrillo-Garcia C, Penarrocha-Oltra D, et al: Rehabilitation of the atrophic posterior maxilla with zygomatic implants: review. *J Oral Implantol* 2011;38:653-657

7. Greenstein G, Cavallaro J Jr: Cantilevers extending from unilateral implant-supported fixed prostheses: a review of the literature. *J Am Dent Assoc* 2010;141:1221-1230
8. Goodacre CJ, Bernal G, Rungcharassaeng K, et al: Clinical complications with implants and implant prostheses. *J Prosthet Dent* 2003;90:121-132
9. Jensen OT, Adams MW, Smith E: Paranasal bone: the prime factor affecting the decision to use transsinus vs zygomatic implants for biomechanical support for immediate function in maxillary dental implant reconstruction. *Int J Oral Maxillofac Implants* 2014;29:130-138
10. Rangert B, Krogh PH, Langer B, et al: Bending overload and implant fracture: a retrospective clinical analysis. *Int J Oral Maxillofac Implants* 1995;10:326-334
11. Zurdo J, Romao C, Wennstrom JL: Survival and complication rates of implant-supported fixed partial dentures with cantilevers: a systemic review. *Clin Oral Impl Res* 2009;20(Suppl.4): 59-66
12. Chrcanovic BR, Abreu MHNG: Survival and complication of zygomatic implants: a systematic review. *Oral Maxillofac Surg* 2013;17:81-93
13. Sharma A, Rahul GR: Zygomatic implants/fixture: a systematic review. *J Oral Implantol* 2013;39:215-224
14. Drago C, Carpentieri J: Treatment of maxillary jaws with dental implants: Guidelines for treatment. *J Prosthodont* 2011;20:336-347
15. Ando T, Maeda Y, Wada M, et al: Contribution of the palate to denture base support: An in vivo study. *Int J Prosthodont* 2014;27:328-330
16. Cavallaro JS Jr, Tarnow D: Unsplinted implants retaining maxillary overdentures with partial palatal coverage: report of 5 consecutive cases. *Int J Oral Maxillofac Implants* 2007;22:808-814
17. Carlsson GE: Clinical morbidity and sequelae of treatment with complete dentures. *J Prosthet Dent* 1998;79:17-23
18. Hirsch JM, Ohnell LO, Henry PJ, et al: A clinical evaluation of the zygoma fixture: one year of follow-up at 16 clinics. *J Oral Maxillofac Surg* 2004;62(Suppl.2):22-29
19. Bragger U, Karoussis I, Persson R, et al: Technical and biological complications/failures with single crowns and fixed partial dentures on implants: a 10-year prospective cohort study. *Clin Oral Implant Res* 2005;16:326-334
20. Kreissl ME, Gerds T, Muche R, et al: Technical complications of implant-supported fixed partial dentures in partially edentulous cases after an average observation period of 5 years. *Clin Oral Implants Res* 2007;18:720-726